

# Pelvic floor biometrics in continent and urinary incontinent elderly women

Dumoulin C<sup>1</sup>, Morin M<sup>2</sup>, Fradet S<sup>1</sup>, Kruger J<sup>3</sup>

1. University of Montreal  
2. University of Sherbrooke  
3. University of Auckland

UNIVERSITÉ DE  
SHERBROOKE

Réseau québécois  
de recherche sur  
le vieillissement

IRSC CIHR  
Institut de recherche  
en santé de Québec  
Canadian Institutes of  
Health Research

Fonds de la recherche  
en santé  
Québec

## Hypothesis and Aim of the study

A large number of women 60 years and over experience urinary incontinence (UI) and its negative quality-of-life consequences; however, the pathophysiology of UI in this population is not completely understood.

Thus, this study compared the pelvic floor muscle (PFM) and bladder-neck biometrics of continent and incontinent elderly women using a 3D/4D transperineal ultrasound (TPU) under 3 conditions: rest, PFM maximum voluntary contraction (MVC) and during Valsalva.

We hypothesized that deficiencies in the morphology of the pelvic floor muscles (PFM) and in the support of the bladder neck are partially responsible for stress UI and mixed UI symptoms in older women.

## Study design and Population

**Study Design:** An observational cohort study.

**Population:** Community-dwelling women were recruited from the Montreal's metropolitan area.

### Inclusion criteria:

- 60 years or older
- Continent or reported at least weekly symptoms of stress or mixed UI in the 3 months prior to the evaluation, based on the Urogenital Distress Inventory (UDI).<sup>(1)</sup>
- Exclusion criteria:**
  - Had participated in PFM treatments within the last year
  - Reported risk factors, medical conditions or medications that could have interfered with the study.
  - To control for the potential effects of age, body mass index (BMI) and parity, participants were matched across the two groups based on age, ( $\pm 5$  years), BMI ( $\pm 3\text{kg/m}^2$ ) and vaginal delivery (yes/no; if yes  $\pm 2$  deliveries).

## Methodology

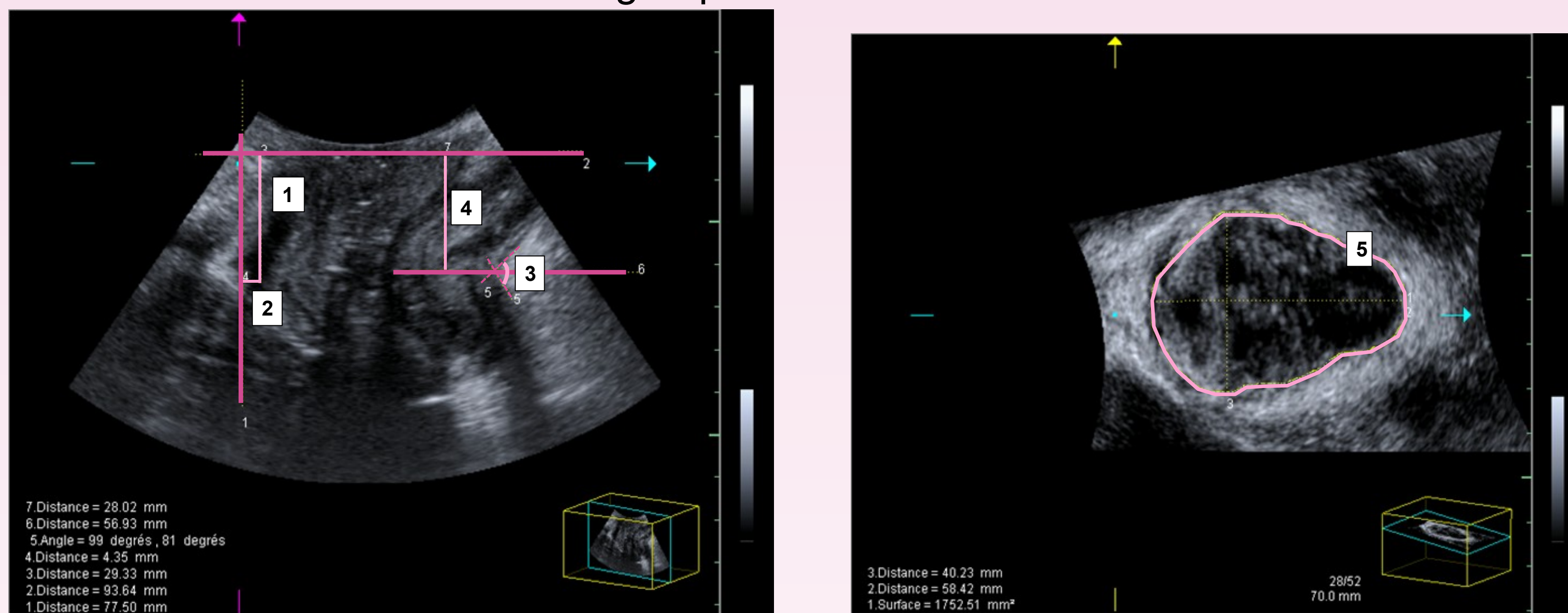
### Experiment:

An experienced physiotherapist taught the women how to perform PFM contractions correctly. Then, transperineal ultrasound (TPU) imaging was performed with participants in a supine position after bladder emptying. Pelvic floor axial and sagittal images were taken under the 3 conditions (rest, PFM maximum voluntary contraction and Valsalva) with an Acuson Antares™ ultrasound (Siemens, USA Inc) using a 3-5 MHz curvilinear 3D probe. Datasets were processed offline using the syngo fourSight™ ViewTool (V3.1) software. The investigator was blinded to the participants' continence status.

One measurement, the levator hiatus area (**LHarea**) (i.e., the area bordered laterally and posteriorly by the pubovisceral muscle and anteriorly by the inferior border of the pubic symphysis), was taken from the axial images, in the plane of minimal dimensions as previously described<sup>(2)</sup> and for all 3 conditions.

Measurements were also taken from the sagittal images; the bladder-neck (**BN**) position (X, Y) at rest, the **BN cranio-ventral displacement** (lift) on contraction and the **BN dorso-caudal displacement** (descent) on Valsalva.<sup>(2)</sup> Finally, **PFM height** (i.e., the perpendicular distance between the ano-rectal angle and the horizontal reference line, originating at the posterior margin of the pubic symphysis) was also measured for all 3 conditions.

As data were normally distributed, independent t-tests were conducted to compare measurements between the two groups.



**Legend:** 1) bladder neck BN position Y, 2) bladder neck BN position X, 3) Anorectal angle, 4) PFM height, 5) LHarea

## Results

Forty women ranging from 60 to 79 years old, a mean age of 67.10 (4.94), participated in the study (20 continent and 20 with UI). There were no differences between the groups in terms of age ( $p=0.45$ ), BMI ( $p=0.44$ ), vaginal deliveries ( $p=0.31$ ), hysterectomies ( $p=0.19$ ), atrophy index scores ( $p=0.63$ ) or hormonal status (0.75); however, UDI scores were significantly different ( $p=0.001$ ).

Intra-rater test-retests were conducted on 20 participants to evaluate measurement reproducibility. The results showed good to excellent reproducibility for all parameters (ICC between 0.71 and 0.94). PFM biometrics for both groups are presented in Table 1.

**Table 1: PFM biometrics in continent and incontinent elderly women**

| Conditions | Measures                     | Continent (n=20) | Incontinent (n=20) | P-Value       |
|------------|------------------------------|------------------|--------------------|---------------|
| Rest       | LH area (mm <sup>2</sup> )   | 1433,00 (345,38) | 1678,26 (316,29)   | <b>0,032*</b> |
|            | BN(Y) (mm)                   | 29,98 (5,77)     | 29,47 (5,16)       | 0,775         |
|            | BN (X) (mm)                  | 7,76 (7,02)      | 9,11 (4,03)        | 0,480         |
|            | PFM height (mm)              | 24,04 (8,43)     | 18,73 (5,72)       | <b>0,031*</b> |
| MVC        | LH area (mm <sup>2</sup> )   | 1102,45 (261,46) | 1450,46 (387,97)   | <b>0,002*</b> |
|            | BN cranio-ventral displ (mm) | 9,16 (5,54)      | 7,96 (5,98)        | 0,514         |
|            | PFM height (mm)              | 26,63 (8,25)     | 18,25 (6,04)       | <b>0,001*</b> |
| Valsalva   | LH area (mm <sup>2</sup> )   | 1885,30 (683,15) | 1878,32 (435,64)   | 0,973         |
|            | BN dorso-caudal displ (mm)   | 18,17 (11,29)    | 18,80 (12,63)      | 0,875         |
|            | PFM height (mm)              | 14,08 (10,79)    | 11,65 (8,33)       | 0,438         |

Results are shown as mean (SD).

## Interpretation of results

At rest, there were significant differences between the UI and continent elderly women for two measurements: the LHarea and PFM height. These differences are indicative of the poorer PFM support or tone found in women with UI.

These measurements also differed between the groups during PFM MVC. These differences are indicative of the contractile-capacity deficit found in women with UI.

On Valsalva however, no significant differences between groups were observed. It is important to note that a levator co-activation was found in some (9/20) incontinent women, which could have confounded the results during Valsalva. Although auditory biofeedback was given by the evaluator, UI women may have refrained from a maximum Valsalva, possibly to prevent leakage.

## Concluding message

- This study is significant in that it is, to our knowledge, the first to look exclusively at pelvic floor biometrics using TPU in elderly women with and without UI.
- Our results suggest that there are differences in pelvic floor morphology between these groups; this group difference also aligns with MRI imaging findings for this subpopulation.<sup>(3)</sup>
- Further, similar intergroup biometric differences were noted in younger and middle-aged incontinent and continent women.<sup>(4)</sup>
- A better understanding of pelvic floor dysfunction in elderly incontinent women is important as it will inform the choice of UI intervention to the one best adapted to a specific dysfunction.

## References

- Shumaker SA, Wyman JF, Uebersax JS, McClish D, Fantl JA. *Health-related quality of life measures for women with urinary incontinence: the Incontinence Impact Questionnaire and the Urogenital Distress Inventory*. Continence Program in Women (CPW) Research Group. Qual Life Res. 1994 Oct;3(5):291-306.
- Dietz HP. *Ultrasound imaging of the pelvic floor. Part II: three-dimensional or volume imaging*. Ultrasound Obstet Gynecol 2004; 23:615-25.
- Pontbriand-Drolet, S., et al., 270- *An MRI study: Do PelvicFloor Morphological and Functional Deficits Differ in Women With Stress Compared to Mixed Urinary Incontinence?*. Neurourol Urodyn, 2012. 31(6): p. 1076-8.
- Thompson, J.A., et al., *Comparison of transperineal and transabdominal ultrasound in the assessment of voluntary pelvic floor muscle contractions and functional manoeuvres in continent and incontinent women*. Int Urogynecol J Pelvic Floor Dysfunct, 2007. 18(7): p. 779-86.

